

SHORT TERM STUDY ON CLINICAL RELEVANCE AND OUTCOMES OF FOETAL HYDRONEPHROSIS

J. S. Randhawa¹, *N. Rajendran², J. Husain², R. Shankaran¹, V. V. Nair², S. Dorai B.³

1 – INSTITUTE OF NAVAL MEDICINE, INHS ASVINI, MUMBAI, MAHARASHTRA, INDIA

2 – ARMED FORCES MEDICAL COLLEGE, PUNE, MAHARASHTRA, INDIA

3 – TATA MEMORIAL HOSPITAL AND RESEARCH CENTRE, MUMBAI, MAHARASHTRA, INDIA

Background. Hydronephrosis is the most common urinary tract pathology detected on antenatal screening by Ultrasound. The detection of fetal hydronephrosis by ultrasound presents a treatment dilemma to the treating surgeon and parental anxiety.

Objective. This study aims to examine the role of serial ultrasounds in antenatally detected fetal hydronephrosis to know the disease progression, and to assess indications and timing of surgery in these patients to preserve renal function.

Methods. This is an observational study of 30 cases of foetal hydronephrosis conducted at a tertiary care paediatric surgery centre. A foetal renal pelvic Antero-posterior diameter (APD) >7 mm at 32 weeks of gestation is considered to indicate Foetal hydronephrosis. These patients are followed up for a period of two years from 2018 to 2020. Progression of disease and need for surgical intervention is noted.

Results. The study comprised 30 cases of antenatal foetal hydronephrosis (42 renal units). Of 26 renal units with mild hydronephrosis, all are resolved in the post-natal period. Of 10 renal units with moderate hydronephrosis, 3 (30%) resolved and 7 (70%) worsened and required surgical intervention. Of 6 renal units with severe hydronephrosis, all required surgical intervention and underwent surgery between 12 to 18 months of age.

Conclusions. These results suggest a grading system with antero-posterior diameter of renal pelvis distinguishes those cases with moderate and severe degrees of hydronephrosis that are at higher risk of surgery.

KEYWORDS: antero-posterior renal pelvic diameter; antenatal fetal hydronephrosis; pyeloplasty.

Introduction

Antenatal ultrasound surveillance detects significant fetal anomaly in 1% of pregnancies; 20-30% of them are genitourinary cases, and 50% – manifest as hydronephrosis [1]. Much of the controversy arises from diagnostic dilemmas and difficulties in distinguishing lesions which are obstructive and potentially harmful to the developing fetal kidney. Controversy remains on the efficacy of therapeutic intervention due to limited knowledge of the underlying natural history and determining appropriate outcome measures. Furthermore, early diagnosis of hydronephrosis may cause anxiety to parents in rest of the pregnancy. Early onset of fetal hydronephrosis is directly related to prognosis [2]. Antenatally detected hydronephrosis is diagnosed if the renal pelvic

AP diameter equals or exceeds 4 mm before 28 weeks or 7 mm thereafter [3].

The study took place at the Tertiary Care Paediatric Surgery Centre to assess the progression and disease course of antenatally detected fetal hydronephrosis. The issue which is still ambiguous at present and is the area of much study is how to differentiate a dilated but non obstructed system from a dilated and obstructed system [4]. To alleviate this pitfall, an integrated approach right from antenatal ultrasonogram to the latest available investigation techniques including DMSA, scintigraphy scan was performed to deepen the understanding of progression of disease in patients with suspected PUJ obstruction [5].

Follow up of antenatally detected fetal hydronephrosis with serial ultrasounds was carried out to identify the disease progression in terms of antero-posterior diameter of renal pelvis. Clinical and imaging parameters were

*Corresponding author: Nagamahendran Rajendran, Clinical Tutor, Department of Surgery, Armed Forces Medical College, Pune, Maharashtra, 411040, India.
E-mail: nagaa.mahendran@gmail.com

analyzed in antenatal and postnatal period to assess the functional status of Urinary system. The indication and right time for surgical intervention was assessed to preserve renal function. This understanding of the functional status of the urinary system also guides in timely surgical intervention.

Methods

This observational study was done at the Tertiary Care Centre in the Department of Paediatric Surgery after due permission from the Institutional Ethics Committee and after taking written informed consent from the patients. Once the patients were enrolled for the study, a thorough history and physical examination was done as per proforma (Table 1).

The complete profile with clinical, radiological imaging and renal scan details were taken as per study proforma and were followed up and outcomes were assessed for complete resolution, partial resolution and persisting cases requiring surgical intervention (Fig. 1).

The antenatal USG at around 32 weeks was performed to diagnose ANH, and renal pelvic anteroposterior diameter (APD) between <7mm was taken as mild, 7-10 mm was taken as moderate and >10mm was taken as severe hydronephrosis (Table 2, 3).

Imaging with ultrasound: all new-borns with history of ANH underwent postnatal USG between days 3-7 of life (Table 4).

Neonates with suspected posterior urethral valves, oligohydramnios or severe bilateral hydronephrosis underwent ultrasonography within 24-48 hours of birth [6]. Subsequent ultrasounds were done at 4-6 weeks, 3 months, 6 months, and 6 monthlies thereafter till resolution/correction. Two consecutive normal ultrasounds were considered as the criteria for resolution.

Voiding Cystourethrogram: VCUG was performed for cases with moderate to severe hydronephrosis, if hydronephrosis worsens on follow up USG, presence of ureteral dilatation, features of lower urinary tract obstruction and in urinary tract infection.

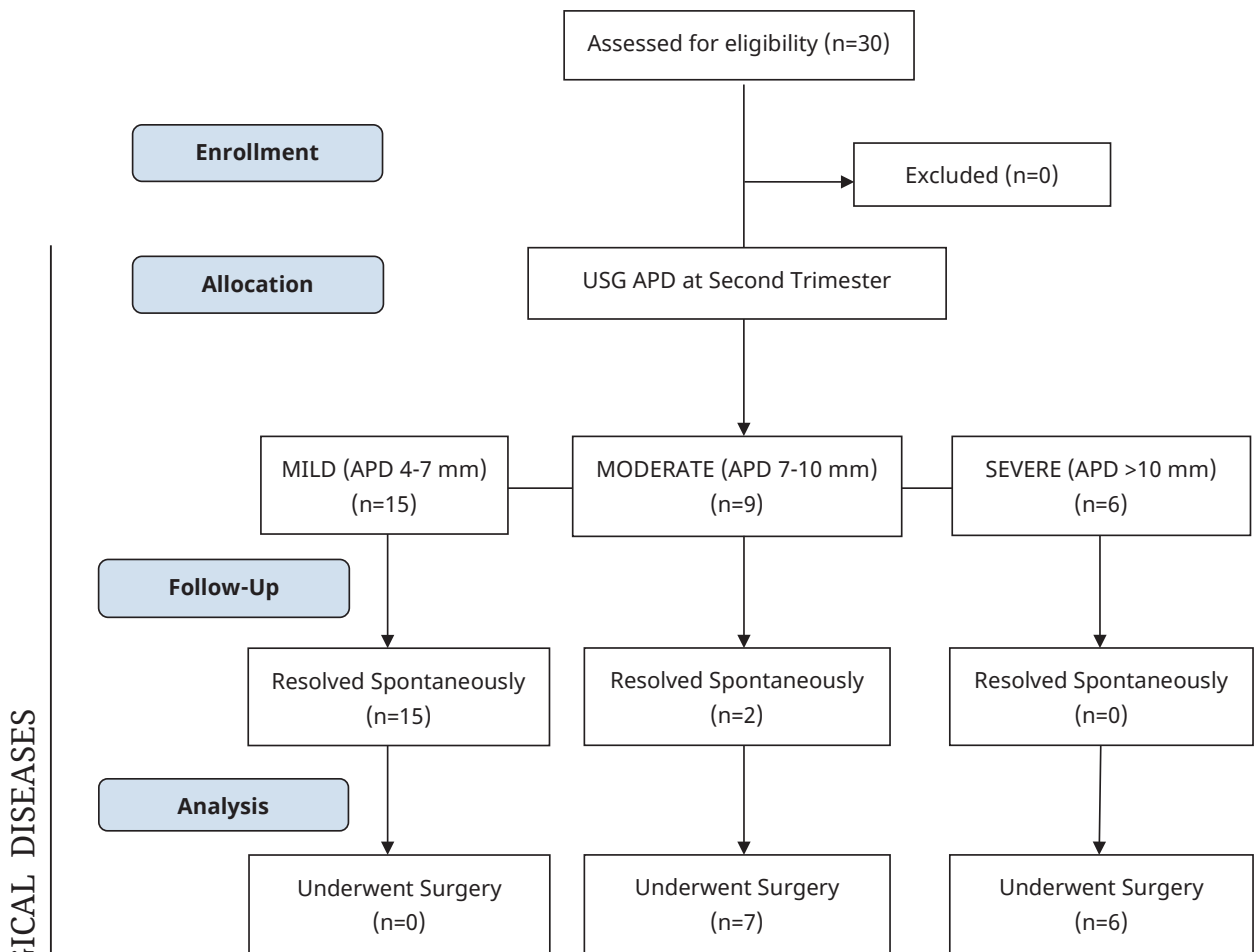


Fig 1. Consort flow diagram.

Table 1. Demographic data

Parameter		No. of patients	No. of kidneys
Gender	Female	8 (26.67 %)	10
	Male	22 (73.33 %)	32
Affected side	Left	12 (40 %)	12
	Right	6 (20 %)	6
	Bilateral	12 (40 %)	24
Second Trimester USG	Mild	15 (50 %)	26
	Moderate	9 (30 %)	10
	Severe	6 (20 %)	6
Third Trimester USG	Resolved	13 (43.33 %)	24
	Mild	4 (13.3 %)	4
	Moderate	5 (16.66 %)	6
	Severe	8 (26.66 %)	8

Table 2. Severity of ANH, second trimester (kidneys=42)

U/L VS B/L	Mild 4-7 mm (n=26)	Moderate 7-10 mm (n=10)	Severe >10 mm (n=6)
	No of kidneys	No of kidneys	No of kidneys
Unilateral	4 (15.38%)	8 (80%)	6 (100%)
Bilateral	22 (84.62%)	2 (20%)	0 (0%)

Table 3. Severity of ANH, third trimester (kidneys=42)

U/L VS B/L	Resolved (n=24)	Mild 4-7 mm (n=4)	Moderate 7-10 mm (n=6)	Severe >10 mm (n=8)
	no of kidneys	no of kidneys	no of kidneys	no of kidneys
Unilateral	2 (8.33%)	4 (100%)	4 (66.67%)	8 (100%)
Bilateral	22 (91.67%)	0 (0%)	2 (33.33%)	0 (0%)

Table 4. Severity of ANH, post-natal (kidneys=42)

U/L VS B/L	Resolved (n=26)	Mild 4-7 mm (n=0)	Moderate 7-10 mm (n=4)	Severe >10 mm (n=10)
	no of kidneys	no of kidneys	no of kidneys	no of kidneys
Unilateral	4 (15.38%)	0 (0%)	2 (50%)	10 (100%)
Bilateral	22 (84.62%)	0 (0%)	2 (50%)	0 (0%)

Radioisotope Studies: diuretic renography was done at 6-8 weeks of life. Radioisotope studies were done in moderate to severe hydronephrosis, worsening hydronephrosis and dilated ureter on USG.

Antibiotic Prophylaxis: The postnatally confirmed ANH of moderate grade, severe grade or with dilated ureters were put on antibiotic prophylaxis with Syp. Cephalexin 10 mg/kg/day as per our institution protocol till evaluation were complete (Table 5).

Table 5. Descriptive analysis of UTI in study population (n=30)

Urine C/S	Frequency	Percentages
No growth	23	76.67%
Growth	7	23.33%
E. Coli	4	57.14%
Kelbsiella pneumoniae	1	14.29%
Mixed growth	1	14.29%
Staph hominis	1	14.29%

Surgery: The progression of disease was screened by postnatal ultrasound. In cases of persistent and severe hydronephrosis, after assessing the functional status of kidneys, surgery was planned according to the etiology (Table 6, 7).

The type of surgery performed and the ideal timing of surgery were assessed (Table 8, 9).

Quantitative data was presented by the mean and standard deviation. Comparison among the study groups was performed by the unpaired t test as per results of normality test. Qualitative data was presented via the frequency and percentage table. Association among the study groups was assessed by the Fisher test, Student' t-test and Chi-Square test. P value less than 0.05 was taken as significant.

Table 6. Post-natal analysis of operated vs non-operated cases

Severity	Operated	Non-operated
Mild (n=15)	0 (0%)	15 (100%)
Moderate (n=9)	7 (77.78%)	2 (22.22%)
Severe (n=6)	6 (100%)	0 (0%)

Table 7. Operated post-natal pathology (n=13)

Pathology	Operated cases	Percentage
PUJ obstruction	9	69.23%
Vesico ureteric reflux	2	15.38%
Posterior urethral valve	1	7.69%
VUJ obstruction	1	7.69%

Table 8. Descriptive analysis of time of surgery in the study population (n=13)

Time of Surgery	Frequency	Percentages
Within 10 days	1	7.69%
10 days to 6 months	3	23.07%
6 months to 12 months	3	23.07%
12 months to 18 months	6	46.15%

Table 9. Descriptive analysis of surgical procedure done in the study population (n=30)

Post-surgical outcome	Frequency	Percentages
Underwent surgery	13	43.33%
Underwent MAH	9	69.23%
Ureterostomy with ureter reimplantation	3	23.07%
Fulguration	1	7.69%

Results

There was significant male preponderance in the study population; 73% of the study population was comprised by male gender. While comparing right and left APD in cases of unilateral hydronephrosis, left APD was significantly more than the right. Post-natal APD mean difference was also the highest with left sided hydronephrosis. As the trimester increases, distension of urinary bladder was on rise and it was directly proportional to the degree of ANH in the early trimester. Oligohydramnios was an indirect marker for severe congenital ANH with almost 50% of the antenatal mothers had oligohydramnios during

their pregnancy. In our study, out of 30 patients, 17 cases underwent spontaneous resolution.

Those cases with mild hydronephrosis, all were resolved postnatally. In the moderate hydronephrosis cases, some of them were resolved, and in the severe hydronephrosis group, further evaluation and surgical intervention was done in all cases. It was further observed that, for those cases, where outlet obstruction was suspected, radio nuclide studies were completed to assess the excretory function of kidney. 13 patients with persistent severe hydronephrosis in post-natal period underwent further evaluation with MCU and MRU. In those patients, E. coli remained the

most common infectious organism in urine amounting to 57% of cases in patients with symptomatic UTI. Pelvi ureteric junction obstruction was the commonest indication for surgery amounting to 61%.

In the study, most of the infants born with persistent and severe hydronephrosis underwent corrective surgery in 12 months. This complies with the institution protocol of more conservative and follow up approach for definitive period before a surgical decision was taken. Among the operated 13 cases, left sided modified Anderson Hyne's pyeloplasty was the commonest procedure amounting to 62.5% of the cases operated. In the surgical patients, left sided poor functioning kidney was maximum with less than 50 % split function in more than 80 % of the surgical group. There was significant male preponderance in our study population. 73% of the study population was comprised by male gender. While comparing right and left APD in cases of unilateral hydronephrosis, left APD was significantly more than the right. Post-natal APD mean difference was also the highest with left sided hydronephrosis. As the trimester increases, distension of urinary bladder was on rise and it was directly proportional to the degree of ANH in the early trimester. Oligohydramnios was an indirect marker for severe congenital ANH with almost 50% of the antenatal mothers suffering from oligohydramnios during their pregnancy. In the study, out of 30 patients. 17 cases underwent spontaneous resolution.

All cases with mild hydronephrosis were resolved postnatally. In the moderate hydronephrosis cases, some of them resolved and in the severe hydronephrosis group, further evaluation and surgical intervention was done for all cases. It was further observed that, those cases where outlet obstruction was suspected, radio nuclide studies were performed to assess the excretory function of kidney. 13 patients with persistent severe hydronephrosis in post-natal period underwent further evaluation with MCU and MRU. In those patients, E. coli was the most common infectious organism in urine amounting to 57% of cases. Pelvi ureteric junction obstruction was the commonest indication for surgery amounting to 61%.

In the study, the most of the infants born with persistent and severe hydronephrosis underwent corrective surgery in 12 months. This complies with the institution protocol of more conservative and follow up approach for definitive period before a surgical decision was

taken. Among the operated 13 cases, left sided modified Anderson Hyne's pyeloplasty was the commonest procedure amounting to 62.5% of the cases operated. In the surgical patients, left sided poor functioning kidney was maximum with less than 50 % split function in more than 80% of the surgical group.

Discussion

The study reports on the independent association of grading of anteroposterior diameter of renal pelvis and its direct association with the risk for surgical intervention. The results support the use of prenatal and post-natal ultrasonograms in assessment of disease progression. While the renal pelvic APD varies with gestation; bladder distension was also an objective parameter in assessing severity of hydronephrosis. If ANH is detected, a followed up with ultrasound including evaluation for lower urinary tract, renal dysplasia, and extra renal structural malformations is carried out [7]. Two follow up ultrasounds were performed, one in third trimester and the other in postnatal period irrespective of severity of hydronephrosis. In the study 100% of severe hydronephrosis and 77.78% of moderate hydronephrosis needed surgical management. Hence, frequent ultrasound evaluation is suggested in cases with moderate and severe hydronephrosis in 6-8 weekly interval to assess disease progression.

We recommend that all newborns with history of ANH irrespective of any trimester should undergo postnatal ultrasound examination within the first week of life. In neonates with moderate or severe hydronephrosis, ultrasonography should be performed within first or second day of birth. We suggest that a micturating cystourethrogram (MCU) being performed within 4 days of life in patients with unilateral or bilateral, moderate and severe hydronephrosis [8].

Our institution performs diuretic renography after 10 weeks of age in persistent severe and progressing moderate hydronephrosis and repeats the same in the 6th month of post-natal life. Our indication for surgical intervention is persistent severe hydronephrosis with obstruction and with evidence of reduced differential renal function on repeat evaluation [6]. As per our institution protocol, in 12th month of birth, we repeat the diuretic renography and watch for disease progression and worsening of split renal function to decide on surgical correction [9]. The patients were started on oral antibiotics

for all cases of moderate and severe hydronephrosis with Syp Cephalixin as the incidence of UTI in these groups of patients was maximum and E coli was the most commonly isolated organism in urine [10].

Conclusions

The prenatal diagnosis of uropathies is today the main contributor to the evolution of individuals suffering from this disease. When faced with a diagnosis of pyelocalyceal dilation, postnatal observation should be planned in order to minimize parental anxiety and to monitor progression of nephrourological pathology. Because of the extremely elastic nature of the fetal renal system, it was established that an evaluation of antenatal hydronephrosis via ultrasound should be conducted on more than one occasion via a standardized methodology

[11]. The APD grade may be used as reliable predictor of the outcome of fetal hydronephrosis, and may be an independent indicator for post-partum surgery.

Limitations

Single centre observational study

Conflict of Interests

The authors declare no conflict of interest.

Author's Contributions

J. S. Randhawa, Nagamahendran R., Jafar Husain – conceptualization, methodology, formal analysis, writing – original draft, writing – reviewing and editing; Vipin V. Nair, Shankaran R. – data curation, writing – reviewing and editing; Shakthi Dorai B. – investigation, formal analysis.

КОРОТКОСТРОКОВЕ ДОСЛІДЖЕННЯ КЛІНІЧНОЇ ЗНАЧУЩОСТІ ТА НАСЛІДКІВ ГІДРОНЕФРОЗУ ПЛОДА

J. S. Randhawa¹, *N. Rajendran², J. Husain², R. Shankaran¹, V. V. Nair², S. Dorai B.³

1 – INSTITUTE OF NAVAL MEDICINE, INHS ASVINI, MUMBAI, MAHARASHTRA, INDIA

2 – ARMED FORCES MEDICAL COLLEGE, PUNE, MAHARASHTRA, INDIA

3 – TATA MEMORIAL HOSPITAL AND RESEARCH CENTRE, PAREL, MUMBAI, MAHARASHTRA, INDIA

Вступ. Гідронефроз - найпоширеніша патологія сечовивідних шляхів, яка виявляється при допологовому обстеженні за допомогою УЗД. Виявлення гідронефрозу плода за допомогою УЗД ставить перед лікуючим хірургом дилему лікування та викликає занепокоєння у батьків.

Мета. Це дослідження мало на меті вивчити роль серійних ультразвукових досліджень при антенатально виявленому гідронефрозі плода, щоб визначити прогресування захворювання, а також оцінити показання та терміни хірургічного втручання у цих пацієнтів для збереження функції нирок.

Методи. Спостережне дослідження 30 випадків гідронефрозу плода, проведене в центрі дитячої хірургії третинної медичної допомоги. Передньо-задній діаметр ниркової миски плода розміром понад 7 мм на 32 тижні вагітності вважається ознакою гідронефрозу плода. Пацієнти перебували під спостереженням протягом двох років з 2018 по 2020 рік. Відзначалось прогресування захворювання та необхідність оперативного втручання.

Результати. Дослідження охопило 30 випадків антенатального гідронефрозу плода (42 нирки). З 26 нирок з легким гідронефрозом всі одужали в післяпологовому періоді. З 10 нирок із помірним гідронефрозом 3 (30%) одужали, а у 7 (70%) стан погіршився, що вимагало хірургічного втручання. З 6 нирок з важким гідронефрозом всі вимагали хірургічного втручання і були прооперовані у віці від 12 до 18 місяців.

Висновки. Результати свідчать про те, що система класифікації за передньо-заднім діаметром ниркової миски дозволяє розрізняти випадки з помірним і важким ступенями гідронефрозу, які мають вищий ризик хірургічного втручання.

КЛЮЧОВІ СЛОВА: передньо-задній діаметр ниркової миски; антенатальний гідронефроз плода; пієлопластика.

Information about the authors

J. S. Randhawa, Assistant Professor General Surgery & Pediatric Surgeon, Institute Of Naval Medicine, INHS Asvini, Mumbai, Maharashtra, India

<https://orcid.org/0000-0002-0081-7382>, mosheshingh2000@yahoo.co.in

Nagamahendran Rajendran, Clinical Tutor, Armed Forces Medical College, Pune, Maharashtra, India

<https://orcid.org/0000-0002-9854-7236>, nagaa.mahendran@gmail.com

Jafar Husain, Assistant Professor General Surgery, Armed Forces Medical College, Pune, Maharashtra, India

<https://orcid.org/0000-0003-2400-1473>, jafarhusain01@gmail.com

R. Shankaran, Professor and Head, Department of Surgery, Institute Of Naval Medicine, INHS Asvini, Colaba, Mumbai, Maharashtra, India

<https://orcid.org/0000-0002-0105-2270>, drshankaran@gmail.com

Vipin V. Nair, Associate Professor, Armed Forces Medical College, Pune, Maharashtra, India

<https://orcid.org/0000-0001-6903-6368>, vipinvenugopalnair@gmail.com

Shakthi Dorai B., Research Fellow, Oral & Maxillofacial Pathologist, Tata Memorial Hospital and Research Centre, Mumbai, Maharashtra, India

<https://orcid.org/0000-0002-1819-7951>, drshakthidorai@gmail.com

References

1. Sinha A et al. Revised guidelines on management of antenatal hydronephrosis. Indian journal of nephrology 2013;23,2:83-97.
2. Chiodini B, Ghassemi M, Khelif K, Ismaili K. Clinical Outcome of Children with Antenatally Diagnosed Hydronephrosis. Front Pediatr. 2019; 7:103.
3. Has, Recep, and Tugba Sarac Sivrikoz. "Prenatal Diagnosis and Findings in Ureteropelvic Junction Type Hydronephrosis". Frontiers in pediatrics 2020;8 492.4.
<https://doi.org/10.3389/fped.2020.00492>
4. Orabi M, Abozaid S, Sallout B, Abu Shaheen A, Heena H, Al Matary A. Outcomes of Isolated Antenatal Hydronephrosis at First Year of Life. Oman Med J. 2018 Mar;33(2):126-32.
<https://doi.org/10.5001/omj.2018.24>.
5. Miyakita H, Hayashi Y, Mitsui T, Okawada M, Kinoshita Y, Kimata T, Koikawa Y, Sakai K, Satoh H, Tokunaga M, Naitoh Y, Niimura F, Matsuoka H, Mizuno K, Kaneko K, Kubota M. Guidelines for the medical management of pediatric vesicoureteral reflux. Int J Urol. 2020 Jun;27(6):480-90.
<https://doi.org/10.1111/iju.14223>.
6. Zhang D, Sun X, Chen X, Yu B, Li T, Cheng Y, Ye M, Lin L, Ma L, Zhao Y, Li P. Ultrasound evaluation for prediction of outcomes and surgical decision in fetal hydronephrosis. Exp Ther Med. 2019 Aug;18(2): 1399-406.
<https://doi.org/10.3892/etm.2019.7683>.
7. Li B, McGrath M, Farrokhyar F, Braga LH. Ultrasound-Based Scoring System for Indication of Pyeloplasty in Patients With UPJO-Like Hydronephrosis. Front Pediatr. 2020 Jul 2;8:353.
<https://doi.org/10.3389/fped.2020.00353>.
8. Cho HY, Jung I, Kim YH, Kwon JY. Reliability of society of fetal urology and Onen grading system in fetal hydronephrosis. Obstet Gynecol Sci. 2019 Mar; 62(2):87-92.
<https://doi.org/10.5468/ogs.2019.62.2.87>.
9. Asl AS, Maleknejad S. Clinical outcome and follow-up of prenatal hydronephrosis. Saudi J Kidney Dis Transpl. 2012 May;23(3):526-31.
10. Rianthavorn P, Phithaklimnuwong S. The role of antibiotic prophylaxis in mild to moderate isolated hydronephrosis detected in antenatal screening. Investig Clin Urol. 2020 Mar;61(2):200-6.
<https://doi.org/10.4111/icu.2020.61.2.200>.
11. Madden-Fuentes RJ, McNamara ER, Nseyo U, Wiener JS, Routh JC, Ross SS. Resolution rate of isolated low-grade hydronephrosis diagnosed within the first year of life. J Pediatr Urol. 2014 Aug;10(4): 639-44.
<https://doi.org/10.1016/j.jpuro.2014.07.004>.

Received 15 March 2022; revised 30 May 2022;
accepted 15 June 2022.

This is open access article distributed under the Creative Commons Attribution License, which permits unrestricted use, distribution, and reproduction in any medium, provided the original work is properly cited.